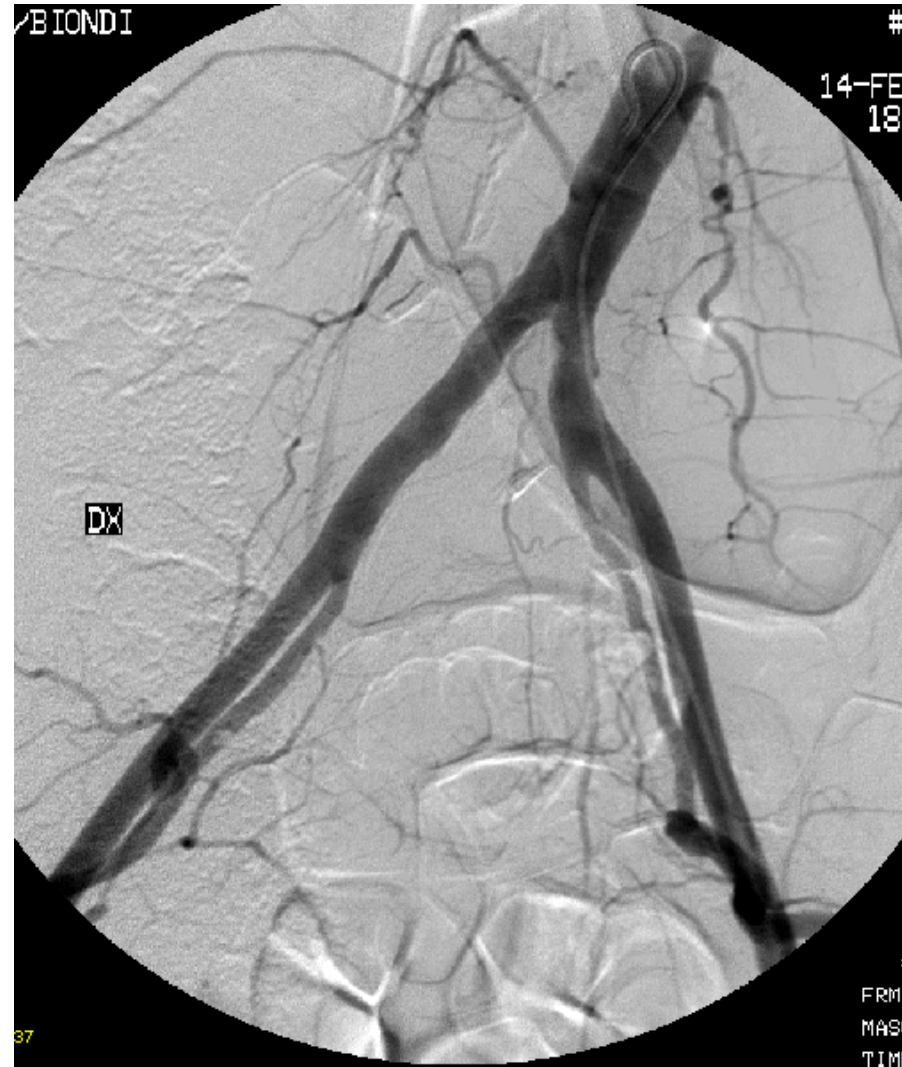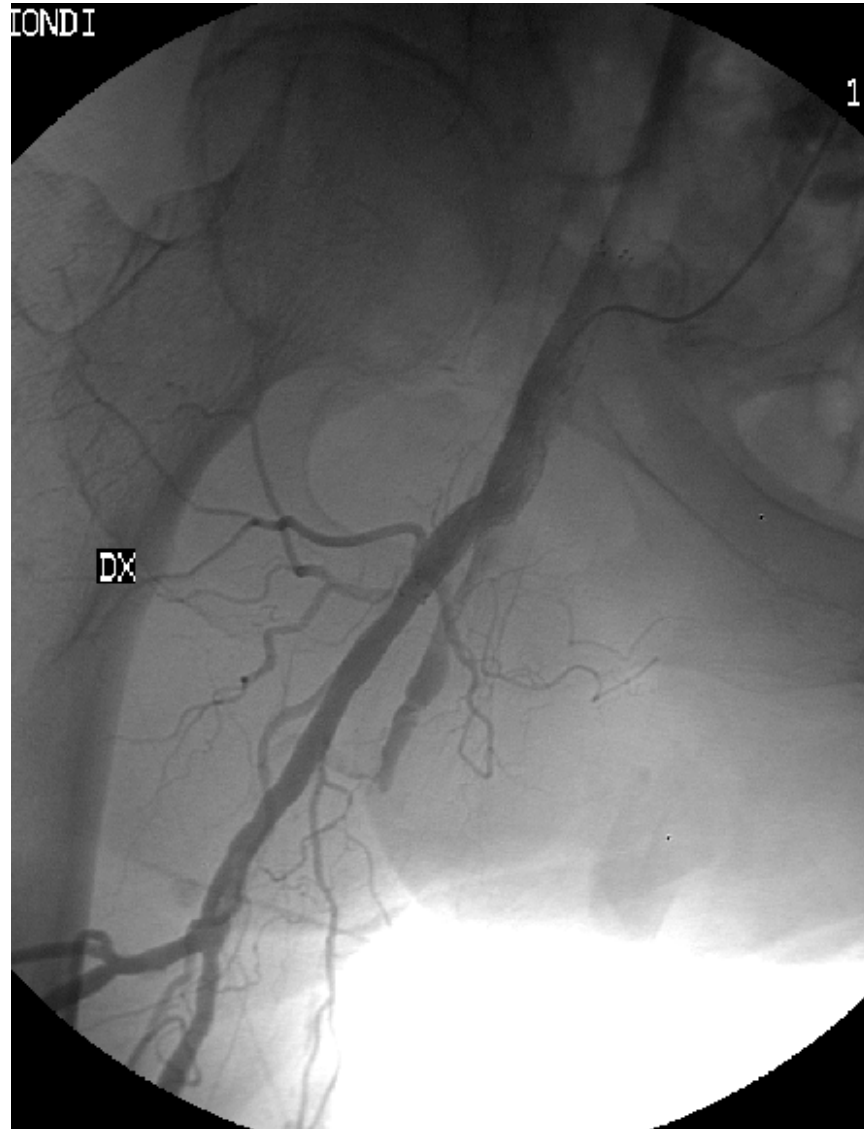


ANTEGRADE ACCESS WITH STENT PUNCTURE

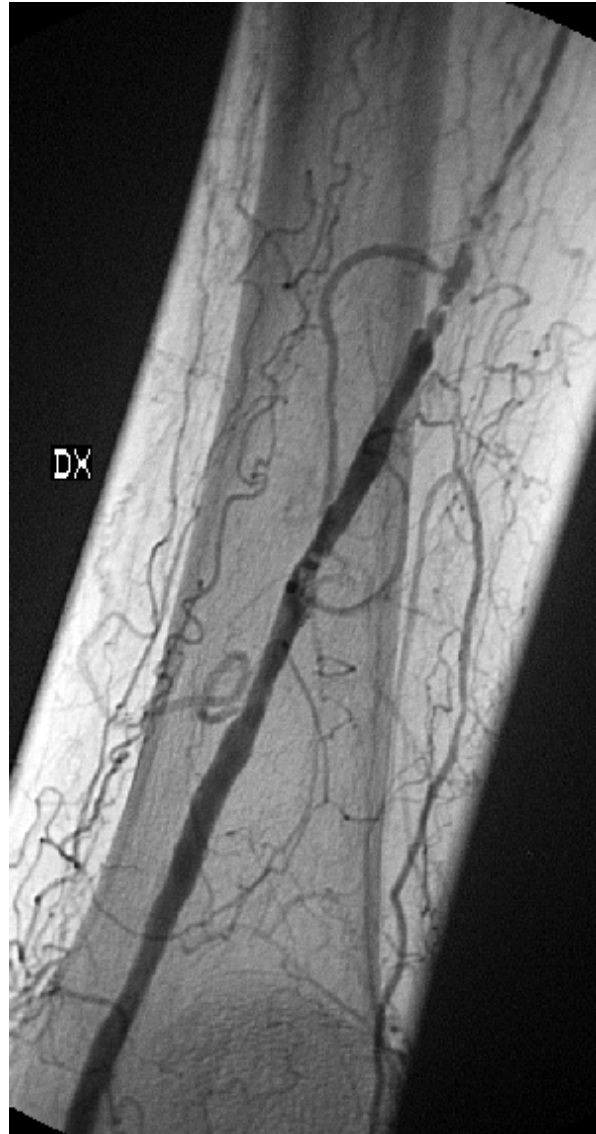LOW RIGHT CFA PULSE



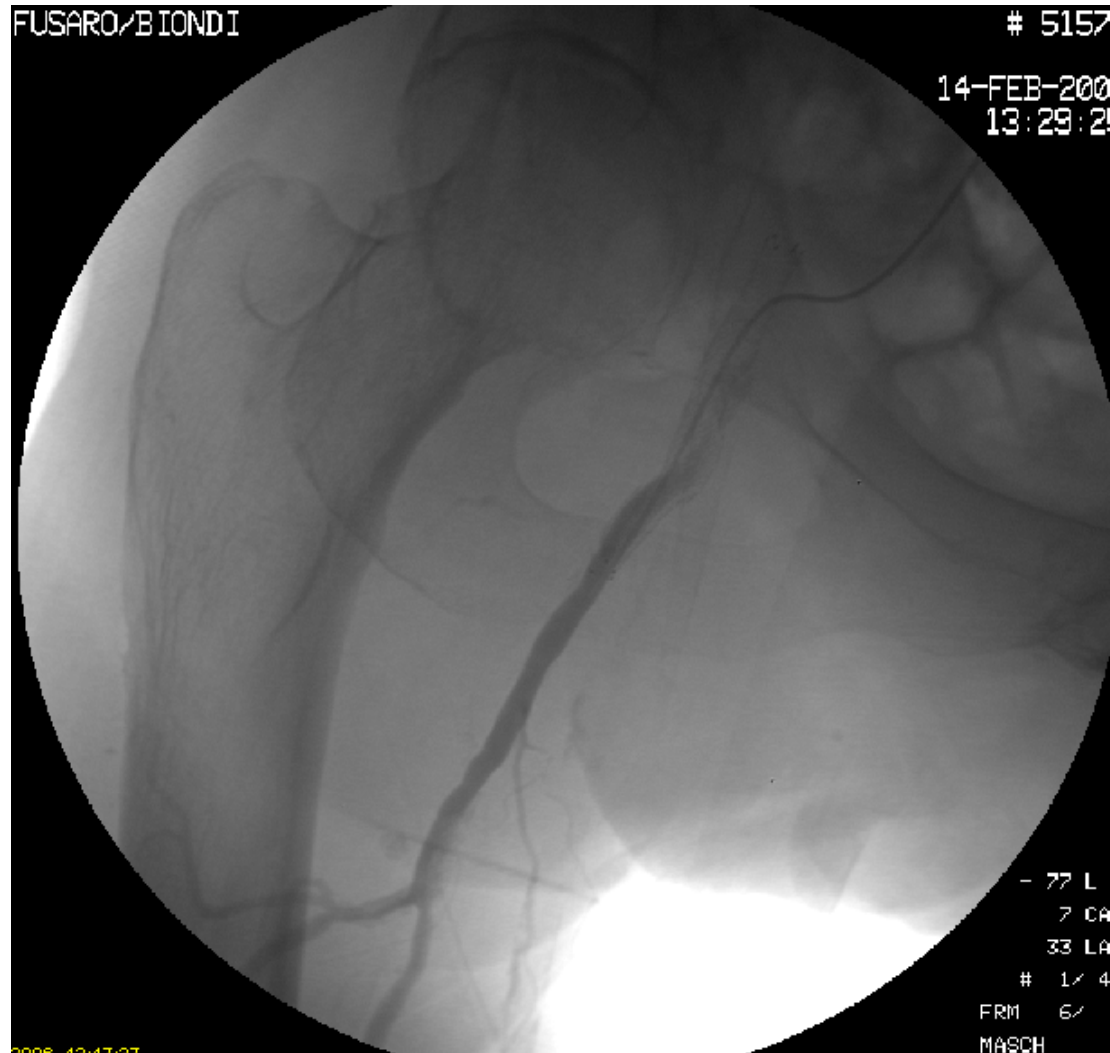
PROXIMAL SFA OCCLUSION



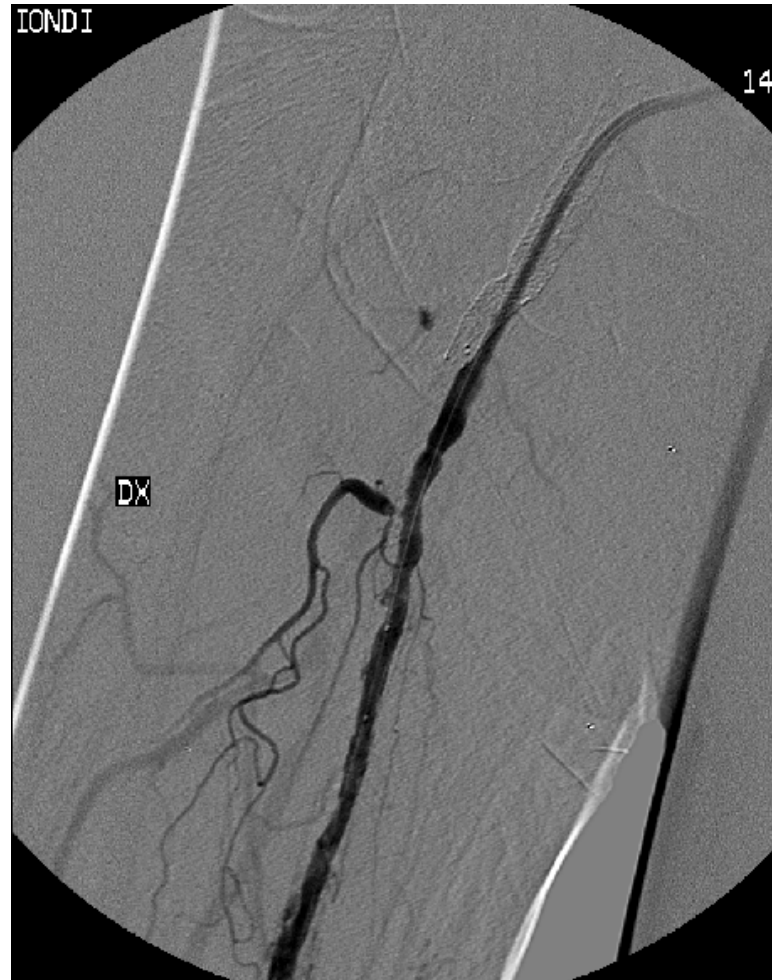WITH DIFFUSE SFA DISEASE



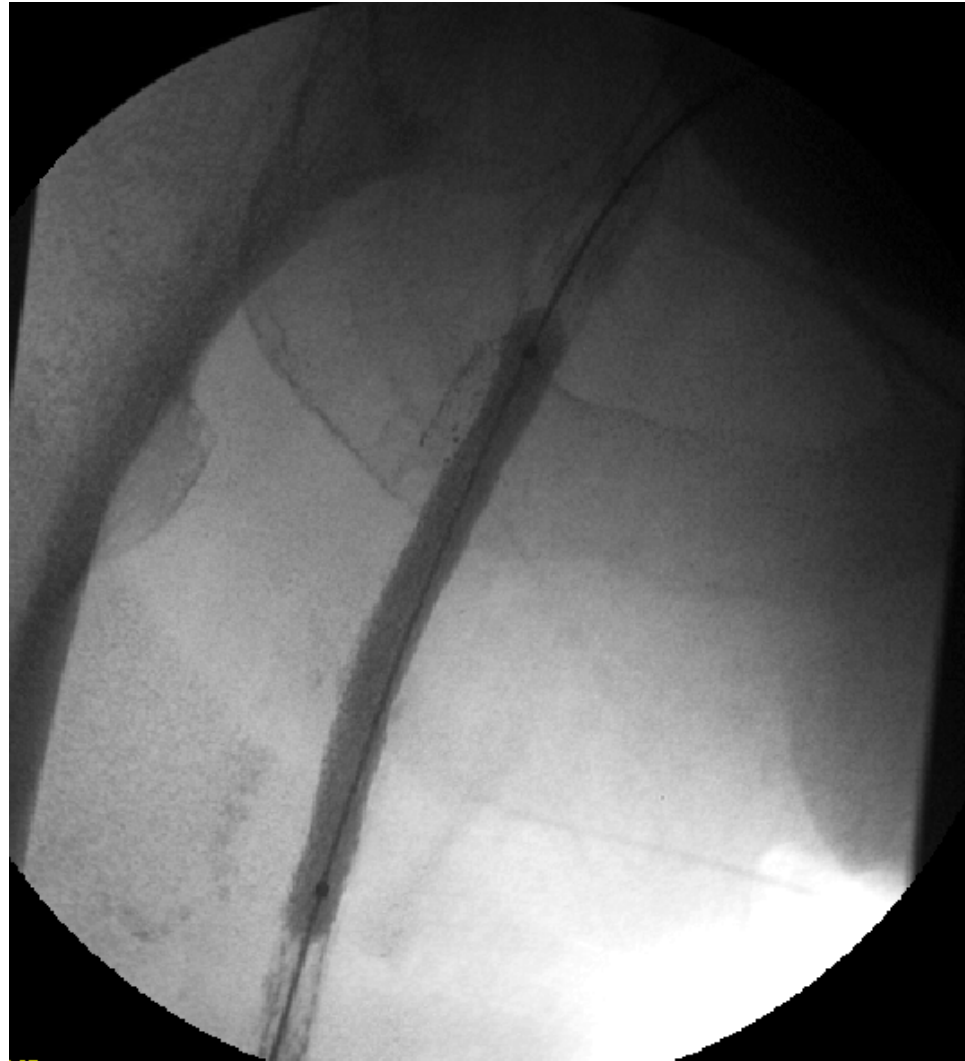
ANTEGRADE CFA STENT PUNCTURE



ANTEGRADE SFA RECANALIZATION



SFA STENTING AND BALLOON



FINAL RESULT

